

CLINICAL PRACTICE GUIDELINES

**MANAGEMENT OF A PATIENT WITH AN
ABNORMAL CERVICAL SMEAR
-
2002 UPDATE**

These guidelines were produced at the request of the *Caisse Nationale d'Assurance Maladie des Travailleurs Salariés (CNAMTS)*, the French National Health Insurance fund for salaried workers. They update and replace the clinical practice guidelines: "Management of the patient with an abnormal cervical smear", which were published in September 1998 by the French National Agency for Accreditation and Evaluation in Health (ANAES).

The report was produced by ANAES, using the method described in the guide "Clinical Practice Guidelines – Methodology to be used in France – 1999", published by ANAES.

ANAES consulted the following professional bodies when producing these guidelines:

- *Collège national des généralistes enseignants*
- *Collège national des gynécologues et obstétriciens français*
- *Fédération nationale des collèges de gynécologie médicale*
- *Société française de colposcopie et de pathologie cervico-vaginale*
- *Société française de cytologie clinique*
- *Société française de gynéco-pathologie*
- *Société française d'oncologie gynécologique*
- *Société nationale de gynécologie et obstétrique*
- *Société nationale de médecine générale*
- *Société française de pathologie.*

The work was coordinated by Dr. Nafissa Abdelmoumène, project manager, under the supervision of Dr. Patrice Dosquet, head of the Guidelines Department.

The economic section of the report was produced by Catherine Rumeau-Pichon, head of the Economic Evaluation Department.

Documentary research was coordinated by Nathalie Dunia, with the help of Sylvie Lascols, under the supervision of Rabia Bazi, head of the Documentation Department.

Secretarial services were provided by Catherine Solomon-Alexander.

ANAES would like to thank the members of the Steering Committee, the Working Group, the Peer Review Group and the members of its Scientific Council, who took part in this project.

STEERING COMMITTEE

Dr. Christine Bergeron, pathologist, *Société française de colposcopie et de pathologie cervico-vaginale*, Cergy-Pontoise

Professor Jean-Charles Boulanger, gynaecologist/obstetrician, *Collège national des gynécologues et obstétriciens français*, Amiens

Dr. Damienne Castaigne, *Société française d'oncologie gynécologique*, Villejuif

Dr. Jean-Marc Charpentier, general practitioner, *Centre de documentation et de recherche en médecine générale*, Montreuil

Dr. Béatrix Cochand-Priollet, pathologist, *Société française de cytologie clinique*, Paris

Dr. Robert-Michel Parache, pathologist, *Société française de gynéco-pathologie*, Vandœuvre-lès-Nancy

Dr. David Serfaty, gynaecologist, *Fédération nationale des collèges de gynécologie médicale*, Paris

Professor Marie-Cécile Vacher-Lavenu, pathologist, *Société française de cytologie clinique*, Paris

WORKING GROUP

Professor Marie-Cécile Vacher-Lavenu, pathologist, Paris - Chairman

Dr. Aminata Sarr, public health physician, Paris - Report author

Dr. Jean-Pierre Vallée, general practitioner, Colleville-Montgomery – Report author

Dr. Nafissa Abdelmoumène, ANAES, Paris - Project manager

Catherine Rumeau-Pichon, ANAES, Paris - Economist

Professor Jean-Jacques Baldauf, gynaecologist/obstetrician, Strasbourg

Dr. Christine Bergeron, pathologist, Cergy-Pontoise

Professor Jean-Charles Boulanger, gynaecologist/obstetrician, Amiens

Dr. Isabelle Cartier, pathologist, Paris

Dr. Marie-Hélène Cayrol, gynaecologist, Toulouse

Professor Colette Charpin-Taranger, pathologist, Marseille

Dr. Hubert Crouet, gynaecologist, Caen

Dr. Bernard Fontanière, pathologist, Lyon

Dr. Michel Levêque, general practitioner, Thann

Professor Gérard Orth, virologist, Paris.

PEER REVIEW GROUP

Dr. Jocelyne Alzieu, epidemiologist, Blagnac

Dr. Gérard Andréotti, general practitioner, La Crau

Dr. Éric Anger, pathologist, Alençon

Dr. Marc Arbyn, epidemiologist, Brussels

Dr. Dominique Benmoura, gynaecologist, Marseille

Dr. Jean-Michel Bouschbacher, gynaecologist, Metz

Dr. Damienne Castaigne, gynaecologist, Villejuif

Dr. Béatrix Cochand-Priollet, pathologist, Paris

Dr. Suzanne Dat, gynaecologist, Toulouse

Professor Jean Gondry, gynaecologist/obstetrician, Amiens

Dr. Rose-Marie Dautry, gynaecologist, Paris

Professor Philippe Delvenne, pathologist, Liège

Dr. Jean Derrien, gynaecologist, Lyon

Dr. Catherine Dormard, general practitioner, Saclay

Professor Jean Douvier, pathologist, Dijon

Dr. Véronique Ezratty, gynaecologist, Paris

Dr. Jean-Pierre Ferry, general practitioner, Audincourt

Dr. Alain Fignon, gynaecologist, Tours

Dr. Éric Fondrinier, surgeon specialising in gynaecology, Angers

Professor Bernard Gosselin, pathologist, Lille

Dr. Monique Gry, general practitioner, Besançon

Dr. Michèle Lagarrigue, gynaecologist, Tours
Professor Jean-Pierre Lefranc, surgeon
specialising in gynaecology, Paris
Dr. Anne-Marie Lehr-Drylewicz, general
practitioner, Parçay-Meslay
Professor Jean-Louis Leroy, gynaecologist/
obstetrician, Lille
Dr. Jean Liaras, pathologist, Limonest
Dr. Jean-Claude Magnier, gynaecologist, Paris
Dr. Monique Marien, gynaecologist, Meyzieu
Dr. Pierre Méchal, general practitioner, Chilly-
Mazarin

Dr. Philippe Morice, surgeon specialising in
gynaecology, Villejuif
Dr. Alain Petitjean, pathologist, Besançon
Professor Denis Querleu, gynaecologist/
obstetrician, Lille
Dr. Patrick Raulic, gynaecologist, Lyon
Dr. Xavier Sastre-Garau, pathologist, Paris
Dr. Jacques Saurel, gynaecologist, Le Bouscat
Professor Henri Sevestre, pathologist, Amiens
Dr. Denis Tramier, gynaecologist/obstetrician,
Aix-en-Provence
Dr. Pascal Tranbaloc, pathologist, Paris
Dr. Marianne Ziol, pathologist, Bondy

GUIDELINES

I. INTRODUCTION

I.1. Subject and target audience

The guidelines on “Management of a patient with an abnormal cervical smear” were produced in 1998 and dealt with:

- cervical smears;
- diagnostic follow-up after an abnormal cervical smear;
- treatment of histological lesions of the cervix detected during cervical smear screening.

This 2002 update deals only with cervical smears and diagnostic follow-up after an abnormal cervical smear. The 1998 guidelines on treatment are still valid. The guidelines are intended for gynaecologists/obstetricians, medical gynaecologists, oncologists, pathologists, laboratory analysts, general practitioners and midwives.

I.2. Aims

Six million cervical smear tests are carried out every year in France in the course of individual testing of women for cervical cancer. When cytological abnormalities of the cervix are revealed by a smear test, the challenge is to choose the most appropriate diagnostic or monitoring procedure for the type of abnormality detected. The cytology report uses the consensus terminology of the Bethesda System, updated in 2001.

The liquid-based cervical smear test and the test for “potentially carcinogenic”¹ human papillomavirus (HPV) have been developed since 1998. Like the conventional Papanicolaou smear test, the liquid-based medium smear test comes under the general heading “diagnostic cytopathological gynaecological procedure derived from one or more samples taken from different zones” in the French Nomenclature and is reimbursed by National Health Insurance. However, the HPV test is not yet reimbursed (September 2002).

The aims of this update report are:

- to present the 2001 update of the Bethesda system
- to compare the performance of the cervical smear in liquid-based medium to that of the conventional Papanicolaou smear
- to assess the HPV test in terms of its reliability and its place in a management strategy after a cytological abnormality has been detected.

The report does not address ways and means of routine cervical smear screening for cervical cancer, nor the use of the HPV test as a screening tool for cervical cancer.

¹ The working group preferred the term “potentially carcinogenic” to that of “carcinogenic” because these viruses cause infections which usually resolve spontaneously and which only cause cancer of the cervix in a small number of cases of persistent infection.

Certain general recommendations made in the 1998 guidelines continue to apply:

- healthcare professionals need better training in performing cervical smear tests, as a high-quality specimen will reduce the number of smears that are unsatisfactory for evaluation and some false negatives;
- quality assurance needs to be implemented in cytology laboratories;
- any disorders identified by the smear test require clinical follow-up and appropriate treatment.

I.3. Grading of guidelines

Guidelines are graded A, B or C as follows:

- a grade A guideline is based on scientific evidence established by trials of a high level of evidence (e.g. randomised controlled trials (RCTs) of high power and free of major bias, and/or meta-analyses of RCTs or decision analyses based on properly-conducted studies);
- a grade B guideline is based on presumption of a scientific foundation derived from studies of an intermediate level of evidence (e.g. RCTs of low power, well-conducted non-randomised controlled trials or cohort studies);
- a grade C guideline is based on studies of a lower level of evidence (e.g. case-control studies or case series).

In the absence of scientific evidence, the guidelines are based on agreement among professionals.

Guidelines that appear below in italics are updated 2002 guidelines, while those in normal font are 1998 guidelines which are still valid in September 2002. Advances in current knowledge and practice may mean that the guidelines will need to be updated again soon.

II. CERVICAL SMEARS

II.1. Best conditions for taking a cervical smear

A number of recommendations need to be followed to improve cervical smear quality:

- the smear should be taken at least 48 hours after sexual intercourse, not during a menstrual period, local treatment or infection, and, if necessary, after local oestrogen therapy in peri- and postmenopausal women;
- it is important to explain the purpose of the test to the woman, and the procedure that will be used, and to reassure her;
- a vaginal examination should not be performed before the smear is taken, and a lubricant should not be used;
- before the smear is taken, the cervix should be properly exposed using a speculum;
- the specimen should include the whole of the external cervical os and the endocervix.

Conventional cervical smear (Papanicolaou method)

An Ayre spatula should be used, together with a brush or a cotton bud, or a Cervex Brush® or modified Ayre spatula which allow specimens to be taken simultaneously

from the external cervical os and the endocervix (grade A). The sample should be spread evenly and fixed immediately. Hair spray may be used.

Cervical smear in liquid-based medium

The specimen should be taken with an appropriate instrument, as for a conventional cervical smear and suspended in the bottle containing the storage fluid. The clinician does not spread the smear.

Accompanying document

A document containing the following clinical information should be sent to the laboratory or cytology practice, with the specimen:

- patient's first name and surname (maiden name);
- date specimen was taken;
- date of birth;
- date of last menstrual period, or if the woman is peri- or postmenopausal, state this;
- reason for test (screening, check-up);
- any gynaecological or treatment history (treatment of the cervix, chemotherapy, hormone therapy, radiotherapy);
- type of contraception used (hormonal contraceptive, intrauterine device).

Training

All individuals who perform cervical smears should have received appropriate training.

II.2. Interpreting a cervical smear: the 2001 Bethesda system

The 2001 Bethesda system (Boxes 1 & 2) is the only system recommended for the cytology report and applies to all smear techniques. The Papanicolaou classification is obsolete.

This revised system is used to decide whether or not a smear can be evaluated. The SBLB category (1991 system) "satisfactory for evaluation but limited by" was the source of confusion and has been deleted. The specimen can either be evaluated or it cannot. If it cannot be evaluated, the reason for rejection should be specified and should be accompanied by suggestions for improving the quality of a new specimen.

Apart from usual problems (smear not spread, slide broken, slide not labelled), a smear is classified as unsatisfactory for evaluation if:

- less than 10% of the slide is covered by squamous cells;
- more than 70% of epithelial cells are unsatisfactory for evaluation because they are obscured by blood, inflammation, superimposed cells, contamination or artefacts.

These criteria should be applied by all pathologists. Agreement between pathologists that a smear is or is not satisfactory for evaluation is quite reliable (grade B).

An absence of endocervical cells should be recorded in the report, but does not in itself constitute a criterion for classification as unsatisfactory for evaluation. The clinician remains the sole judge of whether a further smear needs to be taken.

Any specimen containing abnormal cells is by definition satisfactory for evaluation.

The classification of cytological abnormalities is summarised in Box 1. Box 2 explains the standard abbreviations used. Cervical smear reports should not contain abbreviations that are not clearly explained.

The main changes introduced by the 2001 revisions of the Bethesda system are:

- the categories “within normal limits” and “benign cellular changes” have been grouped into a single category: “negative for intraepithelial lesion or malignancy”;
- a more restrictive interpretation of “atypical squamous cells”;
- a separate category “adenocarcinoma *in situ*”.

Box 1. 2001 Bethesda system (summary – with adaptations)

SPECIMEN ADEQUACY

- Satisfactory for evaluation
- Unsatisfactory for evaluation (specify reason)

INTERPRETATION/RESULT

- Negative for intraepithelial lesion or malignancy (*NIL/M*).

Specify, where appropriate:

- Organisms: *Trichomonas vaginalis*; fungal organisms morphologically consistent with *Candida* spp.; shift in flora suggestive of bacterial vaginosis; bacteria morphologically consistent with *Actinomyces* spp.; cellular changes consistent with herpes simplex virus;
 - Other non-neoplastic findings: reactive cellular changes associated with inflammation, radiation, intrauterine contraceptive device; glandular cells status posthysterectomy; atrophy.
- Epithelial cell abnormalities:
 - Atypical squamous cells (ASC): of undetermined significance (ASC-US) or cannot exclude HSIL (ASC-H);
 - Low-grade squamous intraepithelial lesion (LSIL), encompassing: koilocytosis/ mild dysplasia/CIN 1;
 - High-grade squamous intraepithelial lesion (HSIL), encompassing: moderate and severe dysplasia, carcinoma *in situ*, CIN 2 and CIN 3. Features suspicious for invasion (not otherwise specified), if invasion is suspected;
 - Squamous cell carcinoma.
 - Glandular cell abnormalities:
 - Atypical glandular cells (AGC): specify endocervical, endometrial or not otherwise specified (NOS);
 - Atypical glandular cells, favour neoplastic: endocervical or not otherwise specified (NOS);
 - Endocervical adenocarcinoma *in situ* (AIS);
 - Adenocarcinoma.
 - Other (list not comprehensive):
 - Endometrial cells in a woman aged 40 years or over.

Specify whether case was examined by automated device, and whether an HPV test was performed.

Educational notes and comments (optional) should be concise and phrased in the form of a suggestion. References to relevant publications may be included.

Box 2. 2001 Bethesda system (abbreviations)

AGC	Atypical Glandular Cells
ASC	Atypical Squamous Cells
ASC-US	Atypical Squamous Cells of Undetermined Significance
ASC-H	Atypical Squamous Cells cannot exclude HSIL
CIN 1	Cervical Intraepithelial Neoplasia*, grade 1
CIN 2 or 3	Cervical Intraepithelial Neoplasia, grade 2 or 3
CIS	Carcinoma <i>in situ</i>
HSIL	High Grade Squamous Intraepithelial Lesion
LSIL	Low Grade Squamous Intraepithelial Lesion
NIL/M	Negative for Intraepithelial Lesion or Malignancy
NOS	Not Otherwise Specified

* “Neoplasia” is used here in the strict etymological sense of the term, to designate any formation of new tissue, benign or malignant.

II.3. Conventional Papanicolaou smear or liquid-based medium?

- A good quality specimen is essential for both methods.
- Smears in liquid-based medium² reduce the number of smears that are unsatisfactory for evaluation.
- Smears in liquid-based medium provide sufficient extra material for further diagnostic tests, particularly an HPV test.
- As of 2002, there is not enough evidence to show that smears in liquid-based medium are more sensitive or, especially, more specific.
- Smears in liquid-based medium are more expensive than conventional smears. Cost/efficacy aspects are unknown as of 2002; they need to be analysed and require further studies.

III. DIAGNOSTIC FOLLOW-UP AFTER AN ABNORMAL CERVICAL SMEAR

III.1. Diagnostic methods available

Colposcopy

The aim of colposcopy is to identify abnormalities in the cervical mucosa and to describe their topography. Its power as a diagnostic tool is limited but it is indispensable for guiding biopsies to obtain a histological diagnosis (grade B).

To improve the quality of the examination, clinicians should describe precisely (grade B):

- the location of the squamocolumnar junction;
- the transformation zone;
- the topography of any lesions;
- signs of serious disorders which will help in determining biopsy sites.

The report should include a diagram showing lesions and biopsy sites. The examination should be performed by a doctor trained in colposcopy.

² The term “smear in liquid-based medium” is used in preference to the cytological terms “cervical smear in liquid-based medium” or “thin-layer smear” or “single-layer smear”, which are synonyms .

After abnormal cytology but normal colposcopy findings (with the squamocolumnar junction clearly visualised), a further cervical smear test should be performed 3–6 months later. If its results are positive suggesting a high-grade lesion, a cone biopsy is indicated, even if colposcopy findings are normal (grade B). If the squamocolumnar junction is not visualised or is poorly visualised, the colposcopy result should be classed as unsatisfactory. A further cytology test should be performed, with cone biopsy if appropriate.

Colposcopically-directed cervical biopsy

In France, a cervical biopsy is normally performed after an abnormal smear, under colposcopic guidance. The biopsy specimen is taken from the most suspicious part of the lesion.

- The biopsy should include both surface epithelium and underlying stroma, so that both purely intraepithelial lesions and lesions invading the stroma can be identified.
- The material biopsied should be satisfactory for evaluation, i.e. it should not show any signs of heat-induced coagulation, and should be fixed rapidly for high-quality embedding and staining.

Microcolposcopy

Microcolposcopy must be considered as an adjunct to colposcopy, which should always be the first choice examination. It may be used when colposcopy has been inadequate (because of either difficulty in visualising the squamocolumnar junction, or a discrepancy between cytology and histology), in order to provide details on indications for surgery and tell how much cervical tissue has to be removed (grade C).

Endocervical curettage

The purpose of endocervical curettage is to find glandular or epithelial endocervical lesions which are inaccessible to colposcopically-directed biopsy. However, the procedure cannot definitely eliminate invasive lesions as the specimen is superficial. It is not recommended during pregnancy.

Genital examination to look for other sites

In a woman with any grade of cervical lesion, the vaginal wall and vulva should be examined methodically and meticulously.

- The whole area of the vaginal wall should be investigated colposcopically when the speculum is withdrawn.
- Examination of the vulva is indicated when the patient has a functional complaint or is immuno-suppressed, or if there is a visible lesion of the vulva.
- The perineal region should be examined routinely if there is a vulval lesion or if the patient is immunosuppressed. The woman's partner should be examined if the woman has a condyloma or intraepithelial cervical neoplasia (CIN), as the HPV virus is transmitted sexually.

HPV detection

HPV infection is a sexually shared infection. In most cases, precancerous and cancerous lesions of the cervix are linked to persistence of potentially carcinogenic HPV infection, described as “high-risk” HPV infection. Polymerase chain reaction (PCR) and hybrid capture are currently the best methods for detecting the DNA of genital HPV (grade B). Only Hybrid Capture II[®] is available on the market in France. Neither the PCR nor hybrid capture test is reimbursed in France (September 2002).

III.2. Diagnostic follow-up after a smear with atypical squamous cells (ASC) (Fig. 1)

The 2001 Bethesda system distinguishes between atypical squamous cells (ASC):

- ASC-US (ASC of undetermined significance). An ASC-US smear corresponds to a CIN 2 or CIN 3 histological lesion in only 5–10% of cases, and very rarely to invasive cancer. If ASC-US are detected, there are three options (grade B) :
 - (i) immediate colposcopy;
 - (ii) a control cervical smear 6 months later: if this smear shows that the cytological abnormalities have disappeared, the patient should be followed-up at regular intervals, with a requirement for 2 normal smears at 12-month intervals, because of the risk of a secondary onset of cancer. If the cytological abnormalities reappear during follow-up, colposcopy must be performed, irrespective of the severity or time of onset;
 - (iii) testing for potentially carcinogenic HPV.
- ASC-H, where a high grade squamous intraepithelial lesion (HSIL) cannot be excluded. An ASC-H smear corresponds to a CIN 2 or CIN 3 histological lesion in 40% of cases, and very rarely to invasive cancer. Immediate colposcopy is recommended if there are atypical squamous cells (grade B).

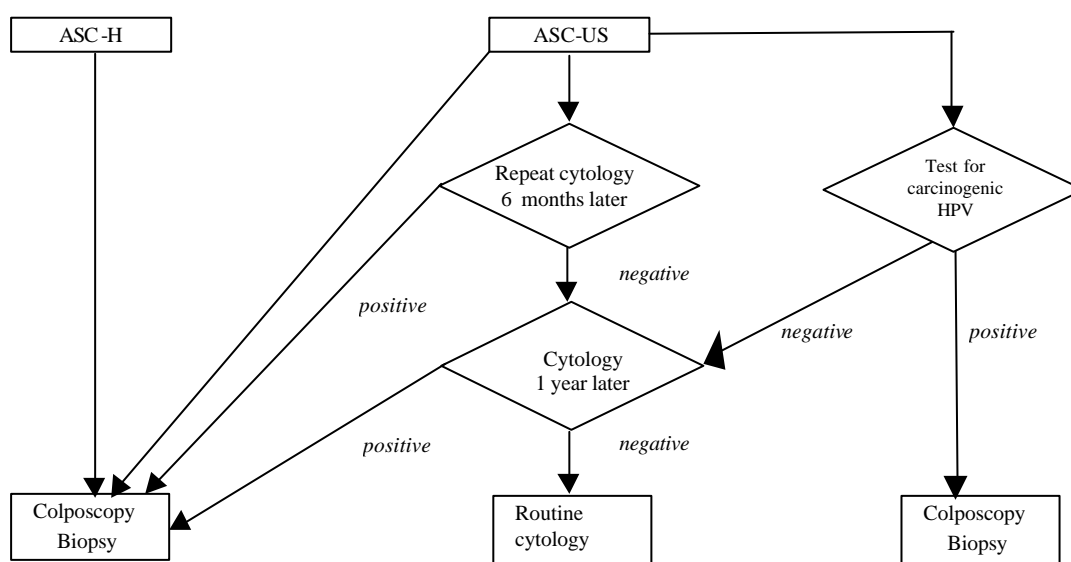


Fig. 1. Management of atypical squamous cells (ASC)

III.3. Diagnostic follow-up after a smear with a low grade squamous intraepithelial lesion (Fig. 2)

The 2001 Bethesda heading “low grade squamous intraepithelial lesions (LSIL)” includes cell changes corresponding to the cytopathogenic effect induced by HPV (koilocytosis) and mild cervical dysplasia (CIN 1). Approximately 2% of standard smears are diagnosed as LSIL. More than half of these lesions regress spontaneously. The remainder persist or occasionally progress to high grade squamous intraepithelial lesions (HSIL) or invasive cancers.

Testing for potentially carcinogenic HPV is not recommended as a first choice in the management of low grade squamous intraepithelial lesions, as the test is positive in more than 80% of these lesions (grade B).

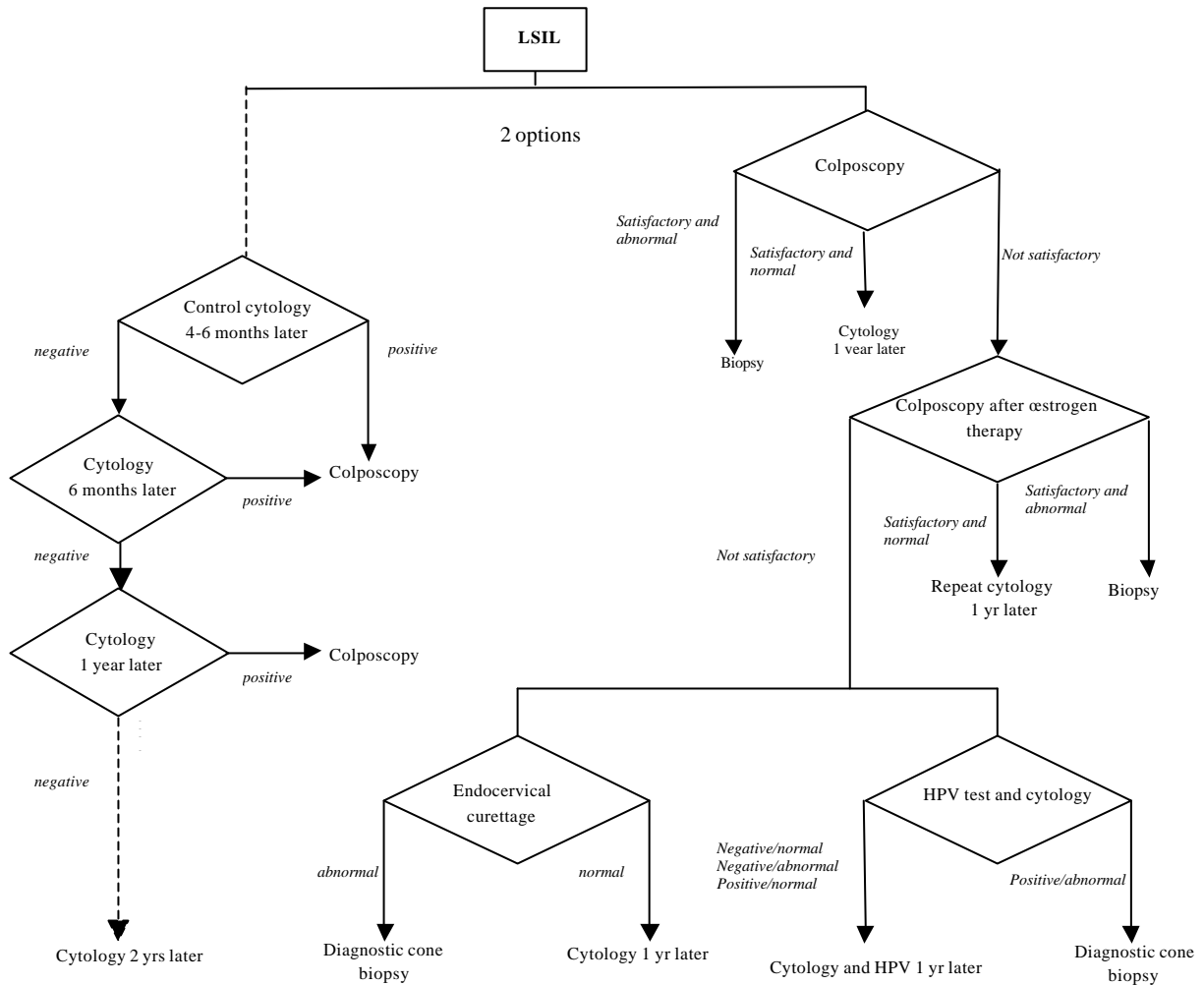


Fig. 2. Diagnostic follow-up after a smear with a low grade squamous intraepithelial lesion (LSIL)

III.4. Diagnostic follow-up after a smear with a high grade squamous intraepithelial lesion (HSIL)

The 1998 guidelines remain valid. Colposcopy should be performed immediately after a cervical smear showing a high-grade squamous intraepithelial lesion (grade B). There is no point in repeating the smear, and it is dangerous to do so because of the risk of missing a more serious lesion and allowing it to develop to become invasive (grade B).

Colposcopy identifies lesions and guides sampling; specimens must be of good quality (grade B).

When colposcopy cannot visualise all the cervical lesions, particularly those located near the endocervical canal, it is classed as unsatisfactory. In high-risk patients (high grade cytology) diagnostic excision is required (grade B).

III.5. Diagnostic follow-up after a smear with atypical glandular cells

The 2001 Bethesda system identifies the following glandular cell abnormalities:

- atypical glandular cells (endocervical, endometrial or not otherwise specified);
- atypical glandular or endocervical cells in favour of neoplasia;
- endocervical adenocarcinoma *in situ* (AIS);
- adenocarcinoma: endocervical, endometrial, extrauterine or not otherwise specified;
- other malignant neoplasms (specified in cytology report).

Colposcopy with colposcopically-directed biopsy and/or endocervical curettage are recommended, irrespective of the type of abnormality of glandular cells (grade B). If the glandular cell abnormalities are endometrial, histological examination of the endometrium should be performed.

If these tests are normal:

- in the case of atypical glandular cells (endocervical, endometrial or not otherwise specified), a further smear should be done at 6 months;
- in the case of cytological abnormalities such as adenocarcinoma *in situ* (AIS) or adenocarcinoma (endocervical, endometrial or not otherwise specified), or suggestive of neoplasm, diagnostic cone biopsy combined with endometrial curettage should be performed.

There is not enough evidence to determine the role of HPV testing in the management of atypical glandular cells.

III.6. Diagnostic follow-up after an abnormal smear in specific situations

In a pregnant woman

Evaluating cytological abnormalities in a pregnant woman simply by taking further smears is inadequate, because there is too little consistency between cytology and histology (grade B). Colposcopy and biopsy are therefore required. In most cases, treatment can be postponed until after delivery, when it can be given under better conditions (grade B).

In patients with biopsy-confirmed CIN, cytology and colposcopy follow-up is recommended at 6–7 months of pregnancy. A further colposcopically-directed biopsy is justified if cytology results or colposcopic findings deteriorate (grade B).

A decision on whether treatment is required should be taken on the basis of the results of a cytological, colposcopic and histological re-evaluation carried out between 6 weeks and 6 months after delivery (grade B).

In very rare cases, cone biopsy may be required during pregnancy (grade B). Cone biopsy is indicated during the first or second trimester if there is a discrepancy between colposcopy, cytology and histology results, and invasive cancer cannot be completely excluded.

After the menopause

Colposcopy performed after local oestrogen therapy for 7–10 days is the gold standard (grade C). If colposcopy is unsatisfactory because of stenosis of the cervical os or if the area of the squamo-columnar junction cannot be visualised, diagnostic cone biopsy is indicated (grade C).

Women who are seropositive for human immunodeficiency virus (HIV)

In view of the frequency of occurrence of CIN in HIV-seropositive women and the lack of correlation between histology and cytology findings, colposcopy should be performed routinely when cytological abnormalities are detected in HIV-positive women (grade B). This is particularly important if the patient is immunodeficient or if there are external genital lesions.

No specific recommendations on HPV testing to screen for high grade squamous intraepithelial lesions in HIV-seropositive women can be made on the basis of current knowledge.

IV. TREATMENT FOR HISTOLOGICALLY DETERMINED CERVICAL LESIONS DETECTED BY CERVICAL SCREENING

IV.1. Treatment indications for histologically determined low grade squamous lesions (LSIL)

Discordant results. If diagnostic results (smear, colposcopy, biopsy) disagree and if the smear and/or colposcopy suggest more serious lesions, the lesion should be excised, by any method, to confirm the histological diagnosis. If the squamocolumnar junction is not visible or is only partially visible, the lesion should be excised, by any method, to confirm the histological diagnosis.

Concordant results. If diagnostic results (smear, colposcopy, biopsy) agree and if the squamocolumnar junction is completely visible, treatment should be decided jointly with the patient, who should be informed of the advantages and drawbacks of each option. The options are:

- immediate treatment, which may involve destruction, preferably using laser ablation;
- monitoring by a smear and colposcopy performed 6 months later, followed by biopsy if necessary. This will result in one of three situations:

- (i) if tests are normal (lesions have disappeared): monitoring by control cytology and colposcopy after 1 year,
- (ii) if the result of any one of the three diagnostic tests deteriorates: excision, by any method,
- (iii) if the abnormalities persist with no deterioration in the result of any one of the three tests: follow-up with control cytology, colposcopy and biopsy every 6 months for a further year, with the same options. If the abnormalities persist after 18 months, destruction or excision by any method may be proposed.

Postoperative follow-up is essential in all cases.

IV.2. Treatment indications for histologically determined high grade squamous lesions (CIN 2 and CIN 3 lesions)

CIN 2 and CIN 3 lesions should always be treated. To choose the method, colposcopy is essential. It should specify the location and size of the lesion and the size of the transformation zone. In the choice of method, the patient's desire to become pregnant and her compliance with post-treatment follow-up should be taken into account.

Excision methods (cone biopsy) are normally indicated. The cone biopsy site should be guided colposcopically. In a young nulliparous woman, the level of the cervical excision should be as small as possible, but within safe limits.

Destructive methods (laser ablation or cryotherapy) may be proposed to women who wish to become pregnant and who agree to attend regularly for follow-up if the following three conditions are met: the lesions must be small, they must be ectocervical lesions only, and they must be fully visualised by colposcopy.

IV.3. Post-treatment follow-up of CIN lesions

Post-treatment follow-up procedures should take account of the imperfect sensitivity of postoperative smears and colposcopy, and of the risk of loss to follow-up. This increases from 7–11% at 6 months after surgery to more than 20% after 2 years.

Regular follow-up may be proposed, with the first check-up at 3–6 months. In view of the imperfect sensitivity of cytology, this follow-up should include colposcopy, cervical smear and colposcopically-directed biopsy and/or endocervical curettage depending on the colposcopic findings and the visibility of the squamocolumnar junction.

- In the absence of abnormalities, examinations should be repeated within 6 months to 1 year, and follow-up will then move on to annual cytology.
- If there are any abnormalities, treatment of histologically confirmed residual lesions should depend on their severity and their location within the cervix. Low grade CIN lesions which are completely visible on colposcopy may be treated by watchful waiting or destruction. High grade CIN lesions and lesions which are not completely visible on colposcopy require further excision. Further excision may be indicated in the event of incomplete excision of a microinvasive lesion or incomplete cervical excision of a CIN lesion when post-treatment stenosis prevents reliable cytological and colposcopic monitoring.

IV.4. Treatment indications and follow-up after treatment of microinvasive squamous cervical carcinomas

Microinvasive carcinoma must be diagnosed from histological examination of the cone biopsy specimen, even if it is suggested by biopsy alone (grade B). Confirmation of microinvasive carcinoma requires serial sections and wide excision (grade C).

Cone biopsy into healthy tissue is an adequate method of treatment for microinvasive squamous cervical carcinoma where invasion is 3 mm or less without lymphatic or vascular emboli (grade B).

Regular follow-up is essential irrespective of treatment (grade B). Follow-up after cone biopsy will be easier if treatment has left the squamocolumnar junction accessible to colposcopic examination.

If there are any lymphatic or vascular emboli, some authors feel that more radical surgery is the best way of assessing the risk to the parametrium and lymph nodes. Endoscopic lymphadenectomy could be a useful method for assessing lymph node status.

The treatment decision should be taken jointly with the patient, depending on whether she wishes to become pregnant, and according to the acceptable surgical risk.

Post-treatment follow-up is the same as follow-up after treatment for invasive cervical cancer.

IV.5. Treatment indications in cervical adenocarcinoma *in situ*

The diagnosis should be established by cone biopsy, endocervical and endometrial curettage.

Cone biopsy may be performed for therapeutic purposes provided that all the following conditions are satisfied (grade C):

- the patient wishes to become pregnant again;
- the specimen should be processed as semi-serial sections;
- the patient accepts and understands the need for regular and frequent follow-up (yearly) with a smear and endocervical curettage;
- the patient has been informed of the risk of relapse and the lack of sensitivity of follow-up methods.
- If these conditions are not satisfied, the patient should be offered a simple hysterectomy (grade C). Hysterectomy is recommended after the patient has completed the pregnancy or pregnancies she wished for.

Loop excision is not an effective treatment for cervical adenocarcinoma *in situ* (grade C).